

Cortical Projection Topography of the Human Splenium: Hemispheric Asymmetry and Individual Differences

Mary Colvin Putnam^{1*}, Megan S. Steven^{2*}, Karl W. Doron³,
Adam C. Riggall², and Michael S. Gazzaniga³

Abstract

■ The corpus callosum is the largest white matter pathway in the human brain. The most posterior portion, known as the splenium, is critical for interhemispheric communication between visual areas. The current study employed diffusion tensor imaging to delineate the complete cortical projection topography of the human splenium. Homotopic and heterotopic connections were revealed between the splenium and the posterior visual areas, including the occipital and the posterior parietal cortices. In nearly one third of participants, there were homotopic connec-

tions between the primary visual cortices, suggesting interindividual differences in splenial connectivity. There were also more instances of connections with the right hemisphere, indicating a hemispheric asymmetry in interhemispheric connectivity within the splenium. Combined, these findings demonstrate unique aspects of human interhemispheric connectivity and provide anatomical bases for hemispheric asymmetries in visual processing and a long-described hemispheric asymmetry in speed of interhemispheric communication for visual information. ■

INTRODUCTION

Until recently, it was methodologically difficult to trace the cortical projection topographies of long white matter fiber tracts of the human brain, particularly the corpus callosum. The earliest comprehensive studies of human callosal projection topography correlated cortical lesion location to subsequent callosal degeneration in the post-mortem brain. These findings were generally consistent with the more extensive studies of callosal connectivity in nonhuman primates but were far less specific and limited in their ability to identify unique features of human anatomy (DeLacoste, Kirkpatrick, & Ross, 1985). The recent development of diffusion tensor imaging (DTI), a neuroimaging technique measuring water diffusion *in vivo*, now makes it possible to characterize the principal direction and relative organization of white matter pathways (Poupon et al., 2001). In this study, we use DTI to begin to develop a precise map of human callosal connectivity in the intact brain, focusing on the most posterior region of the corpus callosum, the splenium.

Anatomical research on interhemispheric connectivity in nonhuman mammals has illuminated three basic organizational principles. First, the general pattern of callosal connectivity appears to be largely determined during prenatal development. Distinct callosal subregions contain fibers from noncontiguous cortical areas that share simi-

lar architectonic features (Seltzer & Pandya, 1986), and there is a general correspondence between callosal region and cortical location (i.e., anterior callosal regions contain fibers from anterior cortical regions, etc.). Thus, along its anteroposterior axis, the corpus callosum is typically divided into four subregions with distinct projection topographies: the rostrum, the genu, the body, and the splenium. Each callosal subregion is unique in terms of axon density, size, and extent of myelination. These regional variations in axon properties might reflect the type of information being transferred within that subregion (Aboitiz, Ide, & Olivares, 2003; Aboitiz & Montiel, 2003; LaMantia & Rakic, 1990). Second, the vast majority of callosal axons connect homologous cortical areas (Garol, 1942; Bailey, Garol, & McCulloch, 1941; McCulloch & Garol, 1941), but there is also a significant number of heterotopic connections (DiVirgilio & Clarke, 1997; Boyd, Pandya, & Bignall, 1971; Rakic & Yakovlev, 1968). Cortical areas receiving heterotopic connections also receive homotopic connections, as well as ipsilateral cortical connections without contralateral counterparts (Schwartz & Goldman-Rakic, 1982; Pandya & Kuypers, 1969). Finally, a significant number of callosal connections connect cortical areas representing midline body regions and are therefore believed to enable the seamless representation of both halves of the body (Berlucchi & Rizzolatti, 1967; Myers, 1962).

Midline fusion is a particularly important and unique aspect of the human visual system because normal vision involves the integration of the independent representations of two eyes. Although complete callosotomy does not disrupt the patient's subjective experience of midline

¹Harvard Medical School, ²Dartmouth College, ³University of California, Santa Barbara

*These authors contributed equally to the work.

fusion, there is considerable evidence that higher order visual functions, including visual tracking across the midline and visual depth comparison using relative motion, are impaired in the absence of the corpus callosum (Naikar & Corballis, 1996; Rivest, Cavanagh, & Lassonde, 1994; Mitchell & Blakemore, 1970; Gazzaniga, Bogen, & Sperry, 1965). There is also limited evidence that complete callosotomy negatively impacts binocular integration at the vertical meridian (Fendrich, Wessinger, & Gazzaniga, 1996). It is yet unclear how the corpus callosum mediates these higher level visual functions; however, it likely involves neurons within the visual cortices that receive callosal input (Saint-Amour, Lepore, Lassonde, & Guillemot, 2004), most of which are located at the border of primary visual cortex (striate cortex, Brodmann's area [BA] 17) and secondary visual cortex (BA 18) in each hemisphere. At least some of these cells are binocular and have receptive fields that encompass the vertical meridian, receiving input through ipsilateral geniculocortical pathways, as well as from contralateral visual cortex via the corpus callosum (Berlucchi & Rizzolatti, 1967).

Neurons involved in midline visual fusion are thought to pass through the splenium, as nonhuman mammal studies have revealed that this callosal region has extensive projections to posterior cortical areas, including the extrastriate regions of the occipital cortex (BA 18 and BA 19; Pandya & Seltzer, 1986; Rockland & Pandya, 1986), but not the striate cortex (Pandya & Seltzer, 1986; Myers, 1962). Recent DTI studies of the connectivity of the human splenium have confirmed the broad conceptualization that the human splenium connects to occipital cortex (Park et al., 2008; Hofer & Frahm, 2006) and have also found that the middle band of the splenium is comprised of fibers originating in dorsal visual areas, whereas the inferior-anterior corner of the splenium is comprised of fibers from ventral visual areas (Dougherty, Ben-Shachar, Bammer, Brewer, & Wandell, 2005). Yet, the detailed cortical connectivity pattern of the entire human splenium remains relatively unknown.

Also unknown is whether there is a hemispheric asymmetry in splenial connectivity. Asymmetric callosal projections might serve to regulate interhemispheric communication between the dominant and the non-dominant hemisphere during performance of any lateralized task. Indeed, asymmetric callosal projections outside the splenium connecting the primary motor cortices have been described, with greater connectivity between the corpus callosum and the dominant (left) hemisphere (Guye et al., 2003). Similarly, greater white matter connectivity between Broca's and Wernicke's areas in the left hemisphere compared with the right hemisphere has been found, and this is presumably related to the lateralization of language functions (Powell et al., 2006). With respect to the visual system, one might also expect asymmetric splenial connections, with greater connectivity in the right hemisphere associated with specialization for higher order perceptual processes (Gazzaniga, 2000).

Perhaps related to this, there is a typical asymmetry in interhemispheric transfer time of visuomotor information, with faster interhemispheric transfer from the right to the left hemisphere than vice versa. Some have proposed that this asymmetry could arise from a hemispheric asymmetry in splenial connectivity, but there is no direct evidence to support this hypothesis (Saron, Foxe, Simpson, & Vaughan, 2003).

Thus, the present DTI study aimed to advance our understanding of the connectivity of the human splenium in four ways: (1) by identifying all cortical regions that connect with the splenium; (2) by characterizing splenial connections as homotopic (i.e., connections between the same cortical region in each hemisphere) or heterotopic (i.e., connections between different cortical regions in each hemisphere); (3) by determining whether there is a hemispheric asymmetry in splenial connectivity (i.e., whether there are more splenial connections with the right hemisphere or with the left hemisphere); and (4) by describing any individual differences between participants in splenial connectivity.

METHODS

Imaging Parameters and Analysis

Twenty-one participants (11 men, age 24–39 years, mean age = 30 years) were recruited from the local community. By self-report, all participants were strongly right-handed. Participants also had no abnormal neurological history and had normal or corrected-to-normal visual acuity. Participants were either paid for their participation or received course credit. All participants gave informed consent in accordance with guidelines set by the Committee for the Protection of Human Subjects at Dartmouth College.

Structural MRI and DTI images were acquired using a 3-T Philips Intera Achieva Scanner (Philips Medical Systems, Bothell, WA) equipped with SENSE (SENSEitivity Encoding) head coil. All neuroimaging took place at the Dartmouth Brain Imaging Center. High-resolution, T1-weighted, three-dimensional anatomical images were used for display and registration into stereotaxic space: 160 contiguous sagittal images; repetition time = 9.9 msec; echo time = 4.6 msec; matrix size = 256×256 ; field of view = 240 mm; and slice thickness = 1.0 mm. DTI was performed using single-shot, spin echo EPI to obtain axial slices ($n = 70$): repetition time = 9023 msec; echo time = 91 msec; flip angle = 90° ; matrix size = 128×128 ; field of view = 240 mm, slice thickness = 2 mm; no gap; and acquisition time = 324 sec. Diffusion weighting was performed along 32 independent directions with a b value of $1,000 \text{ s/mm}^2$. Diffusion-weighted MRI data were analyzed using FMRIB's diffusion toolbox (Centre for the Functional Magnetic Imaging of the Brain [FMRIB], University of Oxford, Oxford, UK; Behrens, Woolrich, et al., 2003).

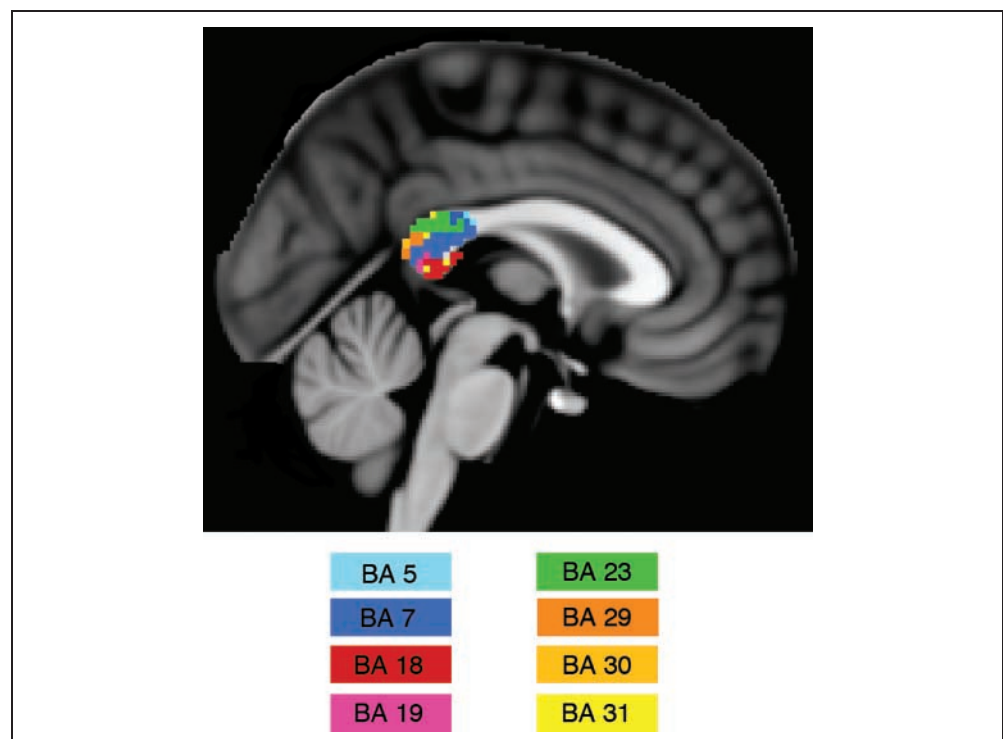
Connectivity Analysis

Determination of Splenium Connectivity

Connectivity of BAs through the splenium was determined using the connectivity-based seed classification option of the FMRIB software library (FSL) tractography software: number of samples = 5000/voxel; curvature threshold = 0.2; number of steps = 2,000; step length = 0.5 mm. The splenium, defined as the posterior 1/5 of the corpus callosum (Witelson, 1989), was the starting seed point; BA masks, generated from the SPM extension WFU PickAtlas (Maldjian, Laurienti, Kraft, & Burdette, 2003), were used as the target regions. A participant was considered to have connections from the splenium to a specific BA if any voxel in the splenium passed a threshold of sending 1,250 of 5,000 (25%) samples or higher to that BA.

We performed an additional analysis to verify our initial finding of homotopic striate connectivity in seven participants. Striate cortex was defined by tracing the geniculocalcarine fibers, or optic radiations, known to exclusively innervate striate cortex (Carpenter, 1991). A mask including an area bordering the temporal horn of the lateral ventricle known to contain the geniculocalcarine fibers was drawn on slice $Z = 37$ of the MNI template brain. An outside investigator independently verified the location of this region. DTI tractography was conducted between the temporal horn region and an occipital lobe mask, thereby identifying voxels in the region of striate cortex above and below the calcarine sulcus. The analysis described above was then performed using this striate cortex mask, verifying the initial results in six of the seven participants.

Figure 1. Topographical organization of splenial projections. Across all participants, at each voxel in the splenium, the cortical region (represented by BAs) to which fibers included in that voxel were most likely to terminate was determined. Of note, BA 17 and BA 29 are also connected through the splenium but are not represented in this figure because axons projecting to these regions were not predominant in any individual voxel.



Determination of Heterotopic and Homotopic Connectivity

To determine whether the connections were heterotopic or homotopic, we used the connectivity-based seed classification option of the FSL tractography software with the following parameters: number of samples = 5000/voxel; curvature threshold = 0.2; number of steps = 2000; step length = 0.5 mm. The starting regions were the individual BAs of the left hemisphere, and the targets were all BAs of the right hemisphere. The splenium was used as a way point with an inclusion mask. This analysis was then repeated with the BAs of the right hemisphere as the starting points and the BAs in the left hemisphere as the targets. A participant was considered to have connections between specific BAs if they passed a threshold of 1250 of 5000 (25%) samples or higher. For each participant, the presence or the absence of homotopic and/or heterotopic connections was noted for each BA, and the total proportion of homotopic and heterotopic connections across the entire brain was calculated.

RESULTS

Cortical Projection Topography of the Human Splenium

Using DTI and probabilistic tractography, we found that the human splenium connects both striate and extrastriate visual areas as well as posterior parietal areas (BAs 5, 7, 17, 18, 19, 23, 29, 30, and 31; Figures 1 and 2). Across all participants, there were a greater number of instances

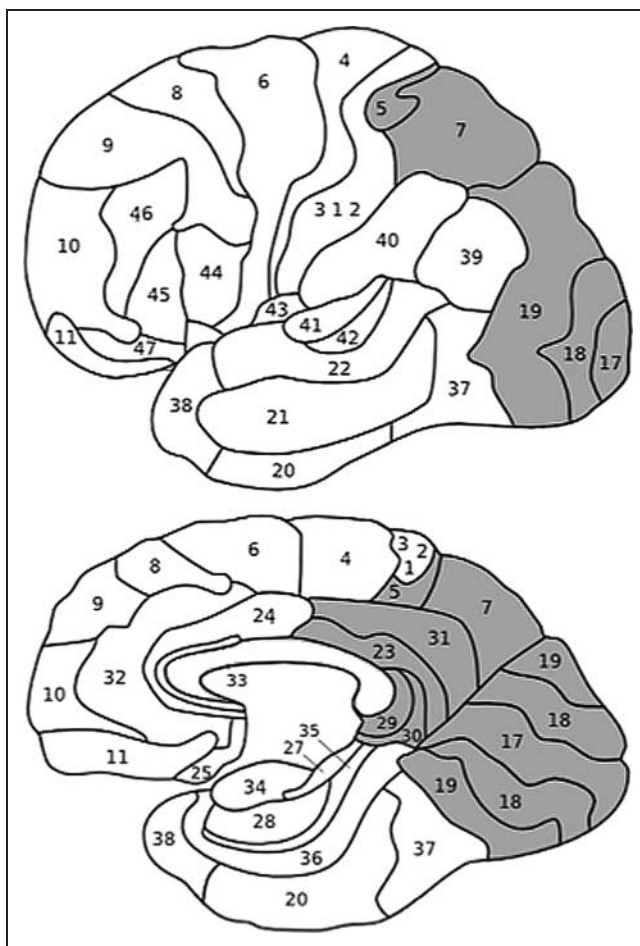


Figure 2. Cortical areas with splenial connectivity. The cortical areas (represented by BAs) that have connections through the splenium are indicated in gray.

of homotopic connections than heterotopic connections, $t(20) = 5.93, p < .001$. These findings are largely consistent with studies of splenial connectivity in nonhuman mammals, although it is worth noting two exceptions. As the splenium was defined in the current study, it also included projections to posterior parietal cortex (BA 7) and did not include projections to the cortical area usually defined as the human parahippocampal gyrus (BA 36).

Individual Differences in Splenial Connectivity

Within the study population, there were marked individual differences in connectivity (Figure 3). In a significant number of individuals ($p < .05$), there were homotopic connections between the splenium and (1) the association cortex of the superior parietal lobe (BA 5, $n = 8$, 38% of the study population), (2) the association cortex between the posterior cingulate gyrus and the medial-temporal lobe (BA 30, $n = 10$, 48% of the study population), and (3) the primary visual cortex (BA 17, $n = 7$, 33.3% of the study population). The latter finding was particularly surprising, given that previous studies in

nonhuman mammals have repeatedly demonstrated that there are no direct callosal projections to striate cortex. We performed an additional analysis to verify these findings (see Methods section) and confirmed that six participants (29% of the study population) were found to have homotopic connections between the splenium and the striate cortex (BA 17). An example of the homotopic connections between the splenium and the BA 17 in a representative participant can be seen in Figure 4.

Hemispheric Asymmetry in Splenial Connectivity

Across the study population, there were greater instances of connectivity from the right hemisphere to the left than from the left hemisphere to the right, $t(20) = 2.82, p = .011$ (Figure 5). Post hoc analyses (paired t tests) revealed that BA 18 and BA 19 drove the main effect of directionality, $t(20) = 2.1, p = .049$ and $t(20) = 2.28, p = .033$, respectively. These post hoc analyses also revealed that there were greater instances of connectivity between the splenium and the BA 29 in the left hemisphere, $t(15) = -2.2, p = .044$ (Figure 5).

Sex Differences

No significant sex differences were found in the relative proportions of homotopic and heterotopic fibers. There were also no sex differences in the extent of the hemispheric asymmetry of splenial fiber projections. A 2×2 mixed-factorial ANOVA ($n = 21$), with the within-subject variable being type of connection (proportions of homotopic and heterotopic connections) and the between-subject variable being sex, was not significant, $F(1, 19) = 0.91, p = .35$. A 2×2 mixed-factorial ANOVA, with the within-subject variable being fiber direction (proportions of connections from the right and left hemispheres, respectively) and the between-subject variable being sex was also not significant, $F(1, 19) = 1.65, p = .22$.

DISCUSSION

The current study presents a comprehensive *in vivo* examination of human splenium connectivity. Consistent with previous studies (e.g., Park et al., 2008; DeLacoste et al., 1985), extensive projections to posterior cortical areas, specifically the parietal and the occipital cortices, were found. Greater homotopic than heterotopic connectivity was also observed, as were significant individual differences in splenial connectivity. Finally, greater connectivity from the right hemisphere to the left was seen, and this was driven by the connectivity of extrastriate visual cortices (BA 18 and BA 19). Below, we discuss these findings with respect to the more extensive studies of splenial connectivity in nonhuman mammals, as well as with regard to how these organizational characteristics may impact human behavior.

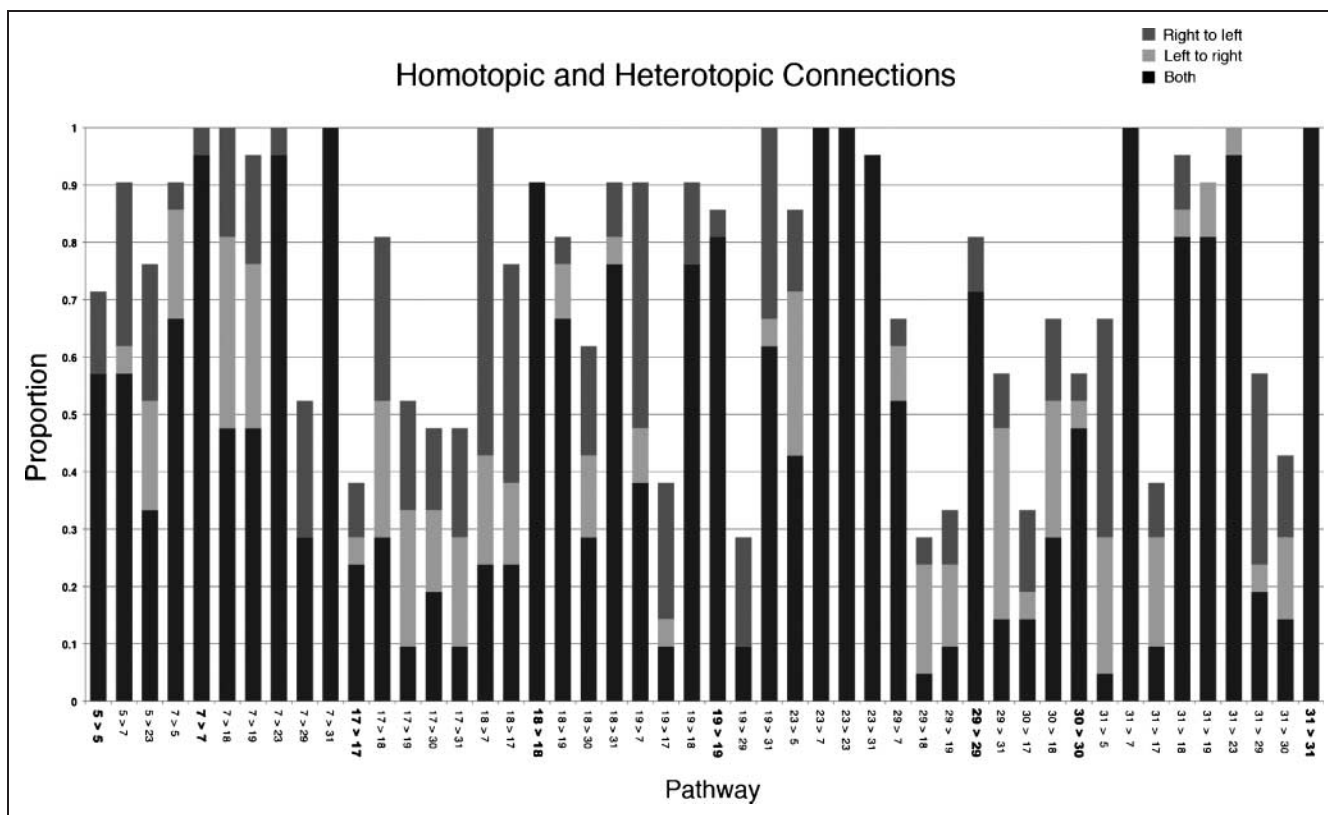


Figure 3. Homotopic and heterotopic splenial connectivity for each cortical region. For each cortical region (represented by BAs) with connectivity through the splenium, it was determined whether these connections were homotopic or heterotopic for each individual participant. The cortical regions of origin and termination are listed on the x-axis (bold items indicate homotopic connections); the proportion of participants is represented on the y-axis. The directionality tractography through the splenium (from the left to the right and the right to the left hemispheres) is also noted (light gray—right to left; medium gray—left to right; dark gray—both hemispheres).

When compared with connectivity patterns described in nonhuman mammals, several distinct features of the human splenium emerged. First, nonhuman mammal studies have revealed splenial projections to the caudal portion of the parahippocampal gyrus (Pandya & Seltzer, 1986). No such connections were found between the human splenium and the region that is typically defined as the human parahippocampal gyrus. Second, studies of nonhuman mammals have not reported splenial projections coursing through to posterior parietal cortex (Saron et al., 2003; Seltzer & Pandya, 1983), such as those described here. These findings suggest interspecies variability in callosal connectivity, although it is possible that these findings may simply reflect differences between the current and the previous studies in defining the boundary of the splenium.

The current study also found evidence for significant interindividual variability in callosal connectivity. Following others who have previously described such individual differences (Park et al., 2008), we cannot rule out that some of these findings resulted from error, due to the current technical limitations of DTI acquisition and processing procedures (e.g., error due acquisition noise, registration, fiber tracking algorithms). However, our high-angular resolution scans (32 gradient directions), the use of FSL's probabilistic algorithms, which are thresholded according

to previously published and validated methods (Behrens, Johansen-Berg, et al., 2003), and the fact that the individual differences reported here were found in a significant proportion of participants give us assurance that these findings are not entirely spurious.

Perhaps the most surprising finding related to individual differences was that one third of participants exhibited direct projections to striate cortex (BA 17). Individual differences in callosal organization have been previously reported for nonhuman mammals (VanEssen, Newsome, & Bixby, 1982), but callosal connectivity to striate cortex has been notably absent in studies of nonhuman mammals (Pandya & Seltzer, 1986; Myers, 1962). This has resulted in the notion that interhemispheric communication does not occur at the level of the primary visual cortex (at least not beyond the vertical meridian) because of the relatively crude nature of visual processing and the available influence of upstream communication. As a result, past researchers have suggested that any homotopic connections between the right and the left primary visual cortices were likely eliminated through axonal pruning during early development (Innocenti & Bressaud, 2003). The current results suggest that there may be variability in this developmental process and at least raise the possibility that these anatomical differences may be related to individual differences in midline fusion.

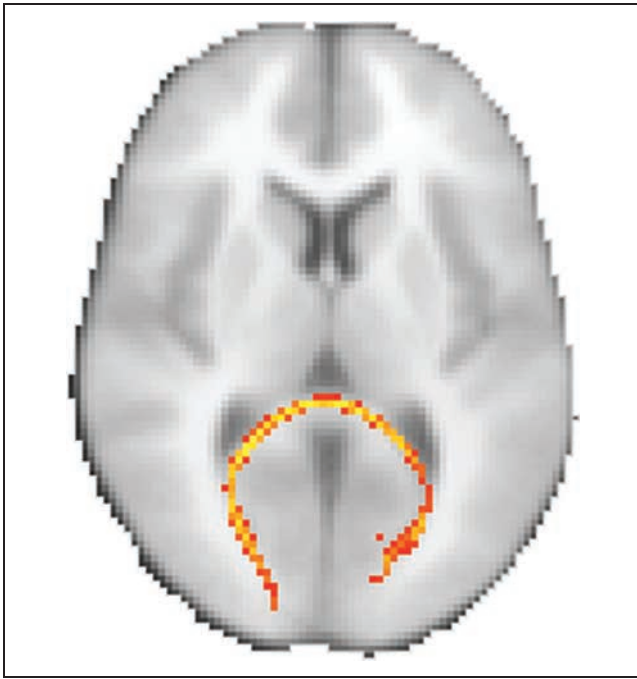


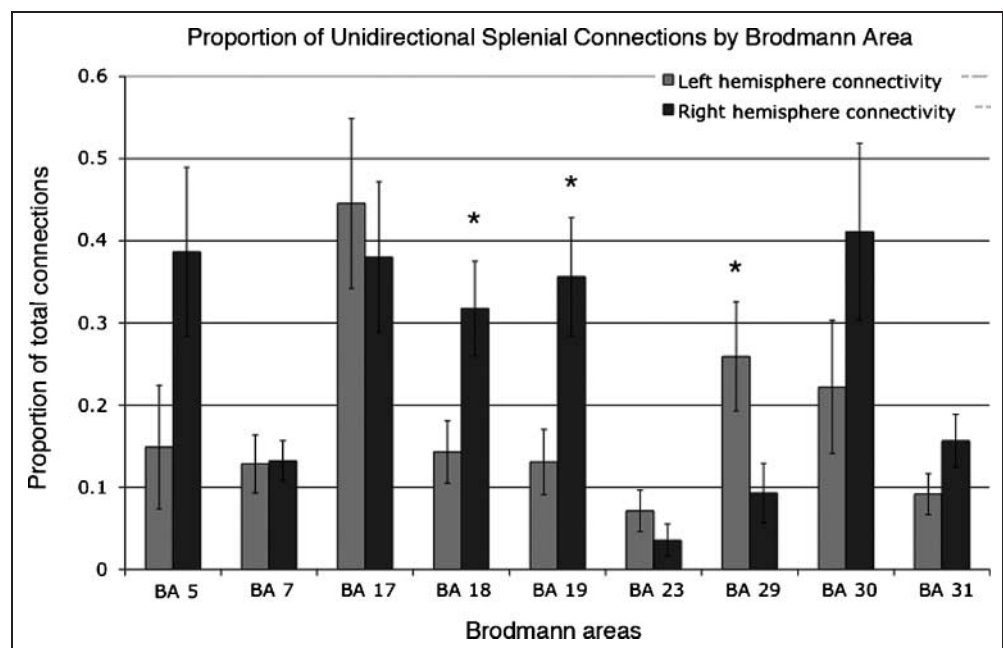
Figure 4. Splenial connections between primary visual cortex. This figure displays the tractography of homotopic connectivity for striate cortex (BA 17) through the splenium in a representative participant who showed such connectivity. Striate cortex (BA 17) was localized by performing tractography from the geniculocalcarine fibers adjacent to the temporal horn of the lateral ventricle. Subsequent tractography revealed splenial connections to the striate cortex in six participants (29% of the study population).

To our knowledge, the current results also represent the first direct evidence of a hemispheric asymmetry in splenial connections between the right and the left hemispheres. Across all cortical regions with projections through the splenium, there were significantly more connections from

the right to the left hemisphere than connections from the left hemisphere to the right (Figure 3). These results are consistent with a recent DTI article describing a nonsignificant trend toward greater numbers of right-to-left fibers across the entire corpus callosum (Zarei et al., 2006). The possibility of a greater splenial connectivity with the right hemisphere has been hypothesized (Saron et al., 2003), on the basis that the left visual cortex is generally larger than the right visual cortex in typically lateralized right-handers (Myslobodsky, Glicksohn, Coppola, & Weinberger, 1991; Kertesz, Polk, Black, & Howell, 1990; Kertesz, Black, Polk, & Howell, 1986). Because axon survival during development is dependent on neurotrophic factors indicating target availability, the smaller right occipital cortex would be relatively more connected through the corpus callosum than visa versa (Saron et al., 2003).

Following the work of others (Barnett & Corballis, 2005; Saron et al., 2003), we propose that this observed hemispheric asymmetry in splenial connectivity is the anatomical basis for the longstanding behavioral observation of a hemispheric asymmetry in the speed of simple visuomotor interhemispheric transfer time. Studies have consistently shown that the magnitude of the difference in simple RTs to visual stimuli presented contralaterally (crossed) or ipsilaterally (uncrossed) to the hemisphere driving the simple motor response (the crossed–uncrossed difference [CUD]) is less when information is transferred from the right to the left hemisphere than when information is transferred from the left to the right hemisphere (Braun, 1992; Marzi, Bisiacchi, & Nicoletti, 1991; Saron & Davidson, 1989a, 1989b; Filbey & Gazzaniga, 1969). Follow-up studies strongly suggested that the origin of the CUD asymmetry might be an asymmetry in callosal anatomy (Bisiacchi et al., 1994; Brown, Larson, & Jeeves, 1994; Marzi et al., 1991), specifically a greater magnitude of callosal connectivity

Figure 5. Proportion of unidirectional splenial connections by BA. For each cortical region with splenial connectivity, the proportion of connections to only the left or the right hemisphere was calculated across all participants ($*p < .05$). Across participants, cortical areas BA 18 and BA 19 showed significantly greater connections from the right hemisphere BAs to the left than from the left hemisphere BAs to the right, indicating that these regions are driving the asymmetry in splenial connectivity. Error bars represent the *SEM* for each cortical region.



from the right to the left visual areas. Our finding of greater connectivity between the splenium and the right extrastriate cortical regions (BA 18 and BA 19) supports this hypothesis, providing an anatomical basis for the CUD asymmetry. From a functional perspective, asymmetric interhemispheric connectivity and interhemispheric communication times might support the development of the right hemisphere's superiority for higher order perceptual processing.

In summary, these data represent a comprehensive *in vivo* examination of the human splenium. Consistent with older studies of callosal cytoarchitecture (e.g., DeLacoste et al., 1985) and recent studies also using DTI (e.g., Park et al., 2008), splenial fibers connected posterior cortical areas, including striate, extrastriate, and posterior parietal areas. Yet the current study also suggests some distinctive features of human splenial connectivity. First, across all individuals, there was greater splenial connectivity from the right hemisphere, particularly to extrastriate cortices. Second, there were significant individual differences in splenial connectivity, including evidence for striatal connectivity in a significant proportion of individuals. These unique characteristics likely influence interhemispheric communication speed of visual information and, by extension, the dynamic distribution of processing resources between the two hemispheres, providing an anatomical basis for individual differences in behavior.

Acknowledgments

The authors would like to thank Dr. Mitchell Glickstein for his assistance and Drs. Scott Grafton and Leo Chalupa for their comments on an earlier version of this article. This work was supported by a grant from the National Science Foundation (NSF SBE-0354400).

Reprint requests should be sent to Michael S. Gazzaniga, Sage Center for the Study of the Mind, University of California, Santa Barbara, Santa Barbara, CA, or via e-mail: m.gazzaniga@psych.ucsb.edu.

REFERENCES

Aboitiz, F., Ide, A., & Olivares, R. (2003). Corpus callosum morphology in relation to cerebral asymmetries in the postmortem human. In E. Zaidel & M. Iacoboni (Eds.), *The parallel brain: The cognitive neuroscience of the corpus callosum* (pp. 33–46). Cambridge, MA: MIT Press.

Aboitiz, F., & Montiel, J. (2003). One hundred million years of interhemispheric communication: The history of the corpus callosum. *Brazilian Journal of Medical and Biological Research*, 36, 409–420.

Bailey, P., Garol, H. W., & McCulloch, W. S. (1941). Cortical origin and distribution of corpus callosum and anterior commissure in chimpanzee (*Pan satyrus*). *Journal of Neurophysiology*, 9, 473–483.

Barnett, K. J., & Corballis, M. C. (2005). Speeded right-to-left information transfer: The result of speeded transmission in right-hemisphere axons? *Neuroscience Letters*, 380, 88–92.

Behrens, T. E., Johansen-Berg, H., Woolrich, M. W., Smith, S. M., Wheeler-Kingshott, C. A., Boulby, P. A., et al. (2003). Non-invasive mapping of connections between human thalamus and cortex using diffusion imaging. *Nature Neuroscience*, 6, 750–757.

Behrens, T. E., Woolrich, M. W., Jenkinson, M., Johansen-Berg, H., Nunes, R. G., Clare, S., et al. (2003). Characterization and propagation of uncertainty in diffusion-weighted MR imaging. *Magnetic Resonance in Medicine*, 50, 1077–1088.

Berlucchi, G., & Rizzolatti, G. (1967). Binocularly driven neurons in visual cortex of split-chiasm cats. *Science*, 159, 308–310.

Bisiachhi, P., Marzi, C. A., Nicoletti, R., Carena, G., Mucignat, C., & Tomaiuolo, F. (1994). Left–right asymmetry of callosal transfer in normal human subjects. *Behavioral Brain Research*, 64, 173–178.

Boyd, E. H., Pandya, D. N., & Bignall, K. E. (1971). Homotopic and nonhomotopic interhemispheric cortical projections in the squirrel monkey. *Experimental Neurology*, 32, 256–274.

Braun, C. M. J. (1992). Estimation of interhemispheric dynamics from simple unimanual reaction time to extrafoveal stimuli. *Neuropsychology Review*, 3, 321–365.

Brown, W. S., Larson, E. B., & Jeeves, M. (1994). Directional asymmetries in interhemispheric transmission time: Evidence from visual evoked potentials. *Neuropsychologia*, 32, 439–448.

Carpenter, M. B. (1991). *Core text of neuroanatomy* (4th ed.). New York: Williams & Wilkins.

DeLacoste, M. C., Kirkpatrick, J. B., & Ross, E. D. (1985). Topography of the human corpus callosum. *Journal of Neuropathology and Experimental Neurology*, 44, 578–591.

DiVirgilio, G., & Clarke, S. (1997). Direct interhemispheric visual input to human speech areas. *Human Brain Mapping*, 5, 347–354.

Dougherty, R. F., Ben-Shachar, M., Bammer, R., Brewer, A. A., & Wandell, B. A. (2005). Functional organization of human occipital–callosal fiber tracts. *Proceedings of the National Academy of Sciences, U.S.A.*, 102, 7350–7355.

Fendrich, R., Wessinger, C. M., & Gazzaniga, M. S. (1996). Nasotemporal overlap at the retinal vertical meridian: Investigations with a callosotomy patient. *Neuropsychologia*, 34, 735–750.

Filbey, R. A., & Gazzaniga, M. S. (1969). Splitting the normal brain with reaction time. *Psychonomic Science*, 17, 335–336.

Garol, H. W. (1942). Cortical origin and distribution of the corpus callosum and anterior commissure in the cat III. *Journal of Neuropathology*, 1, 422–429.

Gazzaniga, M. S. (2000). Cerebral specialization and interhemispheric communication: Does the corpus callosum enable the human condition. *Brain*, 123, 1293–1326.

Gazzaniga, M. S., Bogen, J. E., & Sperry, R. W. (1965). Observations on visual perception after disconnection of the cerebral hemispheres in man. *Brain*, 88, 221–236.

Guye, M., Parker, G. J. M., Symms, M., Boulby, P., Wheeler-Kingshott, C. A. M., Salek-Haddadi, A., et al. (2003). Combined functional MRI and tractography to demonstrate the connectivity of the human primary motor cortex in vivo. *Neuroimage*, 19, 1349–1360.

Hofer, S., & Frahm, J. (2006). Topography of the human corpus callosum revisited—Comprehensive fiber tractography using diffusion tensor magnetic resonance imaging. *Neuroimage*, 32, 989–994.

- Innocenti, G. M., & Bressaud, R. (2003). Callosal axons and their development. In E. Zaidel & M. Iacoboni (Eds.), *The parallel brain: The cognitive neuroscience of the corpus callosum* (pp. 11–26). Cambridge, MA: MIT Press.
- Kertesz, A., Black, S. E., Polk, M., & Howell, J. (1986). Cerebral asymmetries on magnetic resonance imaging. *Cortex*, 22, 117–127.
- Kertesz, A., Polk, M., Black, S. E., & Howell, J. (1990). Sex, handedness, and the morphometry of cerebral asymmetries on magnetic resonance imaging. *Brain Research*, 530, 40–48.
- LaMantia, A. S., & Rakic, P. (1990). Cytological and quantitative characteristics of four cerebral commissures in the rhesus monkey. *Journal of Comparative Neurology*, 291, 520–537.
- Maldjian, J. A., Laurienti, P. J., Kraft, R. A., & Burdette, J. H. (2003). An automated method for neuroanatomic and cytoarchitectonic atlas-based interrogation of fMRI data sets. *Neuroimage*, 19, 1233–1239.
- Marzi, C. A., Bisiacchi, P., & Nicoletti, R. (1991). Is interhemispheric transfer of visuomotor integration asymmetric? Evidence from a meta-analysis. *Neuropsychologia*, 29, 1163–1177.
- McCulloch, W. S., & Garol, H. W. (1941). Cortical origin and distribution of corpus callosum and anterior commissure in the monkey (*Macaca mulatta*). *Journal of Neurophysiology*, 4, 555–563.
- Mitchell, D. E., & Blakemore, C. (1970). Binocular depth perception and the corpus callosum. *Vision Research*, 10, 49–54.
- Myers, R. E. (1962). Commissural connections between occipital lobes of the monkeys. *Journal of Comparative Neurology*, 118, 1–16.
- Myslobodsky, M. S., Glicksohn, J., Coppola, R., & Weinberger, D. R. (1991). Occipital lobe morphology in normal individuals assessed by magnetic resonance imaging (MRI). *Vision Research*, 31, 1677–1685.
- Naikar, N., & Corballis, M. C. (1996). Perception of apparent motion across the retinal midline following commissurotomy. *Neuropsychologia*, 34, 297–309.
- Pandya, D. N., & Kuypers, H. G. J. M. (1969). Cortico-cortical connections in the rhesus monkey. *Brain Research*, 13, 13–36.
- Pandya, D. N., & Seltzer, B. (1986). The topography of commissural fibers. In F. Lepore, M. Ptito, & H. H. Jasper (Eds.), *Two hemispheres—One brain: Functions of the corpus callosum* (pp. 47–73). New York: John Wiley & Sons.
- Park, H.-J., Kim, J. J., Lee, S.-K., Seok, J. H., Chun, J., Kim, D. I., et al. (2008). Corpus callosal connection mapping using cortical gray matter parcellation and DT-MRI. *Human Brain Mapping*, 29, 503–516.
- Poupon, C., Mangin, J., Clark, C. A., Frouin, V., Regis, J., LeBihan, D., et al. (2001). Towards inference of human brain connectivity from MR diffusion tensor data. *Medical Image Analysis*, 5, 1–15.
- Powell, H. W. R., Parker, G. J. M., Alexander, D. C., Symms, M. R., Boulby, P. A., Wheeler-Kingshott, C. A. M., et al. (2006). Hemispheric asymmetries in language-related pathways: A combined functional MRI and tractography study. *Neuroimage*, 32, 388–399.
- Rakic, P., & Yakovlev, P. I. (1968). Development of the corpus callosum and cavum septi in man. *Journal of Comparative Neurology*, 132, 45.
- Rivest, J., Cavanagh, P., & Lassonde, M. (1994). Interhemispheric depth judgement. *Neuropsychologia*, 32, 69–76.
- Rockland, K. S., & Pandya, D. N. (1986). Topography of occipital lobe commissural connections in the rhesus monkey. *Brain Research*, 365, 174–178.
- Saint-Amour, D., Lepore, F., Lassonde, M., & Guillemot, J.-P. (2004). Effective binocular integration at the midline requires the corpus callosum. *Neuropsychologia*, 42, 164–174.
- Saron, C. D., & Davidson, R. J. (1989a). Reliability of visual evoked response estimates of interhemispheric transfer time: Further studies. *Psychophysiology*, 26, S53.
- Saron, C. D., & Davidson, R. J. (1989b). Visual evoked potential measures of interhemispheric transfer time in humans. *Behavioral Neuroscience*, 103, 1115–1138.
- Saron, C. D., Foxe, J. J., Simpson, G. V., & Vaughan, H. G. (2003). Interhemispheric visuomotor activation: Spatiotemporal electrophysiology related to reaction time. In E. Zaidel & M. Iacoboni (Eds.), *The parallel brain: The cognitive neuroscience of the corpus callosum* (pp. 171–219). Cambridge, MA: MIT Press.
- Schwartz, M. L., & Goldman-Rakic, P. S. (1982). Single cortical neurones have axon collaterals to ipsilateral and contralateral cortex in fetal and adult primates. *Nature*, 299, 154–155.
- Seltzer, B., & Pandya, D. N. (1983). The distribution of posterior parietal fibers in the corpus callosum of the rhesus monkey. *Experimental Brain Research*, 49, 147–150.
- Seltzer, B., & Pandya, D. N. (1986). Posterior parietal projections to the intraparietal sulcus of the rhesus monkey. *Experimental Brain Research*, 62, 459–469.
- VanEssen, D. C., Newsome, W. T., & Bixby, J. L. (1982). The pattern of interhemispheric connections and its relationship to extrastriate visual areas in the macaque monkey. *Journal of Neuroscience*, 2, 265–283.
- Witelson, S. F. (1989). Hand and sex differences in the isthmus and genu of the human corpus callosum. *Brain*, 112, 799–835.
- Zarei, M., Johansen-Berg, H., Smith, S., Ciccarelli, O., Thompson, A. J., & Matthews, P. M. (2006). Functional anatomy of interhemispheric cortical connections in the human brain. *Journal of Anatomy*, 209, 311–320.

Copyright of Journal of Cognitive Neuroscience is the property of MIT Press and its content may not be copied or emailed to multiple sites or posted to a listserv without the copyright holder's express written permission. However, users may print, download, or email articles for individual use.